

Mycopathologia

Fungal olecranon bursitis in an immunocompetent patient by *Knoxdaviesia dimorphospora* sp. nov.: case report and review --Manuscript Draft--

Manuscript Number:	MYCO-D-17-00195R1
Full Title:	Fungal olecranon bursitis in an immunocompetent patient by <i>Knoxdaviesia dimorphospora</i> sp. nov.: case report and review
Article Type:	Original Article
Keywords:	bursal infection; olecranon; mould; Microascales; Ascomycota
Corresponding Author:	Josepa Gené, PhD Universitat Rovira i Virgili Reus, Tarragona SPAIN
Corresponding Author Secondary Information:	
Corresponding Author's Institution:	Universitat Rovira i Virgili
Corresponding Author's Secondary Institution:	
First Author:	Marcela Guevara-Suarez
First Author Secondary Information:	
Order of Authors:	Marcela Guevara-Suarez Marta Llauradó Isabel Pujol Emilio Mayayo Adela Martin-Vicente Josepa Gené, PhD
Order of Authors Secondary Information:	
Funding Information:	
Abstract:	<p>Bursitis is a common medical condition that can occur either with or without infection. We present a case of fungal olecranon bursitis in an immunocompetent individual caused by the new species <i>Knoxdaviesia dimorphospora</i>. It is a dematiaceous filamentous fungus characterized by the production of two different conidia: hyaline and cylindrical, which rise up from phialidic conidiogenous cells located in the upper part of differentiated and unbranched conidiophores, and pale brown and ellipsoidal conidia produced by phialidic conidiogenous cells which are born directly on hyphae. In addition to its morphological peculiarities, the novelty of the fungus was confirmed by sequence analysis of the internal transcribed spacer (ITS) regions and D1/D2 domains of the 28S of the nuclear rRNA gene. The fungal infection was confirmed by cytological examination and repeated cultures. The infection was resolved by surgical debridement and drainage, and the patient presented a complete functional recovery three months later. The in vitro antifungal susceptibility to this new human opportunist is provided, terbinafine being the drug with the most potent activity.</p>
Response to Reviewers:	<p>Thank you very much to the reviewers for the suggestions and remarks on the ms MYCO-D-17-00195. We have modified the text accordingly.</p> <p>Our answers to the comments are the following:</p> <p>Reviewer #1:</p> <ol style="list-style-type: none">1. There a few places in the manuscript that need attention to grammar and syntax. <p>The manuscript has been reviewed by an English editor.</p>

[Click here to view linked References](#)

1
2
3
4
5
6
7
8
9
10
11
12
13
14
15
16
17
18
19
20
21
22
23
24
25
26
27
28
29
30
31
32
33
34
35
36
37
38
39
40
41
42
43
44
45
46
47
48
49
50
51
52
53
54
55
56
57
58
59
60
61
62
63
64
65

**Fungal olecranon bursitis in an immunocompetent patient by
Knoxdaviesia dimorphospora sp. nov.: case report and review**

Running title: Olecranon bursitis by *Knoxdaviesia dimorphospora* sp. nov.

Marcela Guevara-Suarez¹, Marta Llaurodo², Isabel Pujol³, Emilio Mayayo⁴,
Adela Martin-Vicente¹, Josepa Gené^{1#}.

¹Unitat de Micologia, Facultat de Medicina i Ciències de la Salut and IISPV,
Universitat Rovira i Virgili, Reus, Spain; ²Servei de Traumatologia i Cirurgia
Ortopèdica, Hospital Universitari Sant Joan, Reus, Spain;³ Laboratori de
Referència Sud, Hospital Universitari Sant Joan, Reus, Spain; ⁴Unitat
d'Anatomia Patològica, Facultat de Medicina i Ciències de la Salut and IISPV,
Universitat Rovira i Virgili, Reus, Spain.

#Corresponding author. E-mail: josepa.gene@urv.cat. Unitat de Micologia,
Facultat de Medicina i Ciències de la Salut, IISPV, Universitat Rovira i Virgili, 21
Sant Llorenç St., 43201, Reus, Spain.

ABSTRACT

Bursitis is a common medical condition that can occur either with or without
infection. We present a case of fungal olecranon bursitis in an
immunocompetent individual caused by the new species *Knoxdaviesia*
dimorphospora. It is a dematiaceous filamentous fungus characterized by the
production of two different conidia: hyaline and cylindrical, which rise up from

1
2
3
4
5
6
7
8
9
10
11
12
13
14
15
16
17
18
19
20
21
22
23
24
25
26
27
28
29
30
31
32
33
34
35
36
37
38
39
40
41
42
43
44
45
46
47
48
49
50
51
52
53
54
55
56
57
58
59
60
61
62
63
64
65

phialidic conidiogenous cells located in the upper part of differentiated and unbranched conidiophores, and pale brown and ellipsoidal conidia produced by phialidic conidiogenous cells which are born directly on hyphae. In addition to its morphological peculiarities, the novelty of the fungus was confirmed by sequence analysis of the internal transcribed spacer (ITS) regions and D1/D2 domains of the 28S of the nuclear rRNA gene. The fungal infection was confirmed by cytological examination and repeated cultures. The infection was resolved by surgical debridement and drainage, and the patient presented a complete functional recovery three months later. The *in vitro* antifungal susceptibility to this new human opportunist is provided, terbinafine being the drug with the most potent activity.

Keywords: bursal infection, olecranon, mould, *Microascales*, *Ascomycota*.

INTRODUCTION

1
2 Bursitis is a common medical condition that can occur either with or without
3
4 infection [1]. Septic bursitis is a frequent cause of musculoskeletal pain and
5
6 often prompts orthopedic consultation. It is almost always preceded by some
7
8 kind of trauma, and the olecranon and the prepatellar bursa are the primary
9
10 kind of trauma, and the olecranon and the prepatellar bursa are the primary
11
12 sites involved [2]. The most frequent cause of bursal infection are bacteria, with
13
14 *Staphylococcus aureus* and *S. epidermidis* being the most common, although
15
16 species of *Streptococcus* or other bacteria have also been reported [1, 3].
17
18 Fungal bursitis is rare and can affect both immunocompromised and
19
20 immunocompetent individuals [4]. Most reported cases cite *Candida* species as
21
22 the cause [5], although cases associated to different filamentous fungi, such as
23
24 *Pleurostomophora*, *Purpureocillium* or *Sporothrix* can also be found in the
25
26 literature [4]. The present report describes a case of septic olecranon bursitis in
27
28 an immunocompetent individual caused by a novel species in the genus
29
30 *Knoxdaviesia* and presents a review of bursal infections by filamentous fungi.
31
32
33
34
35
36
37
38

CASE REPORT

39
40
41 A 46-year-old gardener attended the emergency room due to a left olecranon
42
43 bursitis. The patient reported no prior medical incident of interest or any history
44
45 of trauma. Although no bursal aspiration was carried out for an accurate
46
47 diagnosis, bacterial olecranon bursitis was suspected and empirical treatment
48
49 was started with oral amoxicillin-clavulanic acid (875 mg / 125 mg) every 8
50
51 hours for one week. Although the patient remained afebrile and
52
53 hemodynamically stable, there was no clinical improvement. On physical
54
55 examination, he presented tumefaction, fluctuation, erythema, olecranon
56
57
58
59
60
61
62
63
64
65

1 bursitis pain edema and fluctuation in the left forearm. Additionally, a
2 leukocytosis stood out ($11.94 \times 10^3/\mu\text{l}$) with high C-reactive protein (CRP) of 5.6
3 mg/dl. Due to the bad evolution of the infection, a surgical debridement was
4 performed and a great deal of purulent material was obtained, which was sent
5 for both cytological and microbiological analysis. The lesion was washed with
6 abundant saline solution containing rifampicin and a Penrose drain was placed
7 for 48 hours. A new treatment was started with a higher dose of amoxicillin and
8 clavulanic acid (1000 mg/62.5 mg every 8 hours) for one week, while waiting for
9 the laboratory results. However, the patient's condition improved considerably
10 24 hours after debridement, with a decrease in the erythema and the
11 fluctuation. On analysis, a decrease in the leukocytosis ($7.61 \times 10^3/\mu\text{l}$) as well as
12 the CRP 2.8 mg/dl was proven. Three months later, every inflammatory
13 parameter (leukocytes $8.14 \times 10^3/\mu\text{l}$ and CRP 0.2 mg/dl) was normal, and the
14 patient was completely recovered.
15
16
17
18
19
20
21
22
23
24
25
26
27
28
29
30
31
32
33
34
35

36 **Microbiological and cytological analysis**

37 Two different debridement fluid samples were cultured, following the
38 recommendations of the Spanish Society of Infectious Diseases and Clinical
39 Microbiology [6]. From both samples, numerous colonies of a melanized
40 filamentous fungus with stachybotrys-like morphology were obtained on
41 Sabouraud dextrose agar (SDA; BBL, Baltimore, USA) after 72 h of incubation
42 at 25 and 37 °C. Cultures for bacteria were negative in both samples. For
43 cytological examination, the fluid material was stained with Papanicolaou,
44 Giemsa, periodic acid-Schiff and Grocott's silver methenamine stain and
45
46
47
48
49
50
51
52
53
54
55
56
57
58
59
60
61
62
63
64
65

1 revealed the presence of filamentous fungal elements, consisting of septate and
2 pigmented hyphae, with abundant inflammatory cells (Figure 1).
3
4
5
6

7 **Mycological assessment**

8
9 Two isolates were selected from the SDA cultures and submitted to the
10 Mycology Unit of the Universitat Rovira i Virgili (Reus, Spain) for identification,
11 characterization and *in vitro* antifungal susceptibility testing. The accession
12 numbers in culture collection were FMR 15026 and FMR 15027.
13
14
15
16
17

18 Preliminary cultures of the two isolates on potato dextrose agar (PDA;
19 Pronadisa, Madrid, Spain) at 25 °C produced fast growing, cottony colonies with
20 white mycelia that became greenish black after seven days of incubation in
21 darkness. The two isolates showed similar microscopic features and they were
22 initially identified as *Knoxdaviesia* sp. For further characterization, in addition to
23 PDA, the isolates were studied on malt extract agar (MEA; Difco Laboratories,
24 Baltimore, USA), potato carrot agar (PCA; 20 g potatoes, 20 g carrot, 20 g agar,
25 1000 mL distilled water) and oatmeal agar (OA; 30 g filtered oat flakes after 1 h
26 simmering, 20 g agar, 1000 mL distilled water), incubated at 25°C in the dark.
27 Their ability to grow at 10, 15, 25, 30, 37, 40 and 45 °C was tested on PDA.
28 Color notations used in colony descriptions were from Kornerup and Wanscher
29 [7]. Microscopic features could be observed by making direct wet mounts with
30 85% lactic acid and Shear's solution. Scanning electron microscope (SEM)
31 photographs were also taken using a Jeol JSM- 6400 (Tokyo, Japan) with
32 techniques described previously [8].
33
34
35
36
37
38
39
40
41
42
43
44
45
46
47
48
49
50
51
52
53
54

55 For molecular identification, genomic DNA was extracted from colonies
56 growing on PCA for 7-14 days at 25 °C, and DNA extraction was made using
57
58
59
60
61
62
63
64
65

1 the FastDNA® kit protocol (MP Biomedicals, Solon, OH), according to the
2 manufacturer's instructions. The internal transcribed spacer (ITS) regions and
3
4 D1/D2 domains of the 28S nuclear rDNA (LSU) were amplified with the primer
5
6 pair ITS5/LR5 [9, 10]. Sequencing was carried out in both directions using the
7
8 same PCR primers at Macrogen Europe (Amsterdam, the Netherlands).
9
10 Consensus sequences were obtained using SeqMan version 7.0.0 (DNASar
11
12 Lasergene, Madison, WI).
13
14
15

16
17 BLAST sequence homology searches revealed that the LSU sequences
18
19 (approximately 781 bp) from our isolates showed a 98% similarity with
20
21 sequences of two *Knoxdaviesia* species, i.e. *K. cecropiae* (accession no.
22
23 KM495392) and *K. capensis* (labeled as *Gondwanamyces capensis* accession
24
25 no. EU552136 and EU552135; 100% query coverage). For assertive
26
27 identification, phylogeny was performed using ITS and LSU sequence data.
28
29 Sequences from each locus were aligned with MEGA v 6.0 software [11], using
30
31 the CLUSTALW algorithm [12], refined with MUSCLE [13], and visually adjusted
32
33 on the same software platform. The phylogenetic study was made with
34
35 individual and combined genes using maximum-likelihood (ML) in MEGA v. 6.0.
36
37 For the ML analysis, nearest-neighbor interchange (NNI) was used as the
38
39 heuristic method for tree inference; support for internal branches was assessed
40
41 by 1,000 ML sets of data. A bootstrap support (bs) ≥ 70 was considered
42
43 significant. We included sequences of species of closely related genera, i.e.
44
45 *Custingophora* and *Ceratocystis* [14]. The phylogenetic analysis (Figure 2)
46
47 showed that the case isolates were located in the clade representative of the
48
49 genus *Knoxdaviesia*, forming a fully supported branch, distant from the other
50
51 *Knoxdaviesia* species included in the analysis. Since the isolates represented a
52
53
54
55
56
57
58
59
60
61
62
63
64
65

1 novel lineage and showed morphological features different from the nine
2 species described in the genus [14], they are proposed below as a new species
3 of *Knoxdaviesia*, named *K. dimorphospora*.
4
5

6
7 DNA sequences from FMR 15026 obtained in this study were deposited
8 in GenBank under accession numbers LT671628 for ITS, and LT671629 for
9 LSU.
10
11
12

13 **Antifungal susceptibility**

14
15
16
17 The *in vitro* antifungal susceptibility test was carried out according to the CLSI
18 M38-A2 standard [15]. The drugs tested were amphotericin B (AMB),
19 anidulafungin (AFG), caspofungin (CFG), micafungin (MFG), 5-fluorocytosine
20 (5FC), itraconazole (ITC), posaconazole (PSC), voriconazole (VRC) and
21 terbinafine (TRB). The minimal effective concentration (MEC), defined as the
22 lowest drug concentration at which short, stubby, highly branched hyphae were
23 observed, was determined at 24 h for the echinocandins, and the MIC was
24 determined at 48 h for the remaining drugs. The MIC was defined as the lowest
25 concentration to exhibit 100% inhibition of any visible growth for ITC, PSC, and
26 VRC or 50% and 80% reduction in growth for 5FC, FLC and TRB, respectively.
27
28
29
30
31
32
33
34
35
36
37
38
39
40
41
42
43
44
45
46
47
48
49
50
51
52
53
54
55
56
57
58
59
60
61
62
63
64
65

Candida krusei ATCC 6258 was used as quality control. Terbinafine showed the most potent activity against *K. dimorphospora*, with a MIC ≤ 0.03 $\mu\text{g/ml}$, followed by AMB, VRC and PSC with MIC values of 1.0 $\mu\text{g/ml}$. Among echinocandins, CFG and MFG was also highly effective *in vitro*, with MECs of 0.125 $\mu\text{g/ml}$ and 0.25 $\mu\text{g/ml}$, respectively. AFG, ITC and 5FC were the least active *in vitro* against the case isolates, with a MEC of 8 $\mu\text{g/ml}$, and MICs of 4 $\mu\text{g/ml}$ and >16 $\mu\text{g/ml}$, respectively.

1
2 **Taxonomy**
3

4 *Knoxdaviesia dimorphospora* Guevara-Suarez, Pujol, Llauradó & Gené, sp.
5 nov. (Figure 3). MycoBank accession number MB821526.
6

7 Etymology. Name referred to the presence of two types of conidia.
8

9 Typus. Spain, Catalonia, Reus, from a human olecranon bursitis, Jun. 2016, M.
10 Llauradó & I. Pujol (holotype CBS H-23142; cultures ex-type CBS 142753, FMR
11 15026).
12
13
14
15
16
17

18
19
20 Micromorphology (on PCA at 25°C). *Mycelium* partly superficial and
21 partly immersed, composed of branched, septate, hyaline to subhyaline,
22 smooth-walled, 1 to 2 µm wide hyphae. *Conidiophores* solitary,
23 macronematous, erect, unbranched, 80 to 123 µm long (up to 210 µm on OA),
24 arising from rhizoid foot cells, and terminating in an appressed whorl of 10 to 15
25 phialidic conidiogenous cells; stipe septate, cylindrical, 3.5 to 6 µm wide, often
26 sinuous in the upper part, pale brown to brown, smooth-walled. *Phialides*
27 terminal, cylindrical, 9 to 10(12) by 2 to 3.5 µm, with a minute collarette, pale
28 brown to brown, smooth-walled. *Conidia* aseptate, cylindrical, 7 to 10(12) by 2
29 to 3 µm, with a rounded apex and truncate base, hyaline to subhyaline, smooth-
30 walled, aggregated in slimy masses. A second asexual morph is present in all
31 culture media tested, consisting of groups of clavate phialides, 3 to 4 by 2.5 to 3
32 µm, usually growing laterally on the hyphae or on short stalked cells, up to 6 µm
33 long and to 3 µm wide; conidia ellipsoidal, 8 to 14 by 3 to 5 µm, subhyaline to
34 pale brown, smooth- and thick-walled. Sexual morph not observed.
35
36
37
38
39
40
41
42
43
44
45
46
47
48
49
50
51
52
53
54
55

56 Culture characteristics (in darkness, at 25 °C after 7 d). Colonies
57 attaining 30 to 35 mm diam on MEA, 38 to 42 mm diam on PDA and PCA, and
58
59
60
61
62
63
64
65

1
2
3
4
5
6
7
8
9
10
11
12
13
14
15
16
17
18
19
20
21
22
23
24
25
26
27
28
29
30
31
32
33
34
35
36
37
38
39
40
41
42
43
44
45
46
47
48
49
50
51
52
53
54
55
56
57
58
59
60
61
62
63
64
65

60 to 78 mm diam on OA. On PCA, colonies flat, cottony, greenish grey (26F2) with aerial mycelium white to grey (26D1), margin entire; reverse near black (25F4).

Cardinal temperatures for growth. Optimum 30 to 37 °C, minimum 15 °C, maximum 40 °C.

Differential diagnosis. *Knoxdaviesia dimorphospora* can be distinguished from the other species of the genus by the production of a second phialidic asexual morph and by its profuse growth at 37 °C (61 to 68 mm diam on PDA).

DISCUSSION

Septic bursitis caused by filamentous fungi are rarely described, and most of the cases have been associated to *S. schenckii*. Wang et al. [16] reported a case of bursal sporotrichosis, and found in the literature eight other cases caused by that species. However, since Wang's review, no more case of sporotrichal bursitis have been published. In our review, we found 13 cases of bursal infection caused by filamentous fungi different to *S. schenckii* between 1979–2016 (Table 1). Apart from this latter fungus, no genus or species have been found associated to this type of infection, although *Pleurosthomophora risardsidae* and *Purpureocillium lilacinum* are reported in three and two cases, respectively [17 - 21]. These two species, as well as *Aspergillus terreus*, *Exophiala oligosperma* and *Fonsecaea pedrosoi* have been described previously as human opportunists that can cause both superficial and deep infections [2, 4, 22, 23], wherears *Anthopsis deltoidea* and *Phomopsis bougainvilleicola* are only known from the cases of septic bursitis [24, 25]. It is of note, however, that we found 3 out of 13 cases in which the causal agent has

1 not been identified at the genus or species level [22, 26 - 28]. Therefore, the
2 species diversity of filamentous fungi found is a handicap for establishing the
3 epidemiology, and the proper diagnosis and therapy of this type of infection. In
4 the present study, we describe the first case of human infection caused by a
5 species of *Knoxdaviesia*, in which cytological examination and culturing have
6 been crucial for confirming the infection. However, a detailed phenotypic and
7 molecular characterization has also been required to identify a new fungus, *K.*
8 *dimorphospora*, as human opportunist.

9
10
11
12
13
14
15
16
17
18
19 *Knoxdaviesia* is a genus that currently comprises nine species and it is
20 classified in the order Microascales [14], a group of fungi which includes other
21 relevant human pathogens in the genera *Lomentospora*, *Microascus*,
22 *Scedosporium* or *Scopulariopsis* [4, 29]. Morphologically, *Knoxdaviesia* is
23 clearly distinguished from all them by its large and unbranched conidiophores,
24 usually arising from rhizoids and bearing terminally a whorl of phialidic
25 conidiogenous cells that produce hyaline, one-celled, cylindrical to allantoid
26 conidia, arranged in slimy heads [14]. In addition, some of its species produce
27 the sexual morph, which is characterized by perithecial ascomata with long
28 necks, very similar to those produced by the genus *Ophiostoma* [14, 30]. For
29 this reason, *Knoxdaviesia* are often defined as ophiostomatoid fungi, but
30 phylogenetically they belong to different sordariomycetous orders. *Ophiostoma*
31 is included in the Ophiostomatales and *Knoxdaviesia* in the Microascales, as
32 mention before [14]. Our new species does not produce ascomata, however it
33 shows the typical asexual structures of the genus with cylindrical conidia and
34 also produces a second type of asexual morph (synanamorph) with ellipsoidal
35 and pale brown conidia. Although the synanamorph production is reported for
36
37
38
39
40
41
42
43
44
45
46
47
48
49
50
51
52
53
54
55
56
57
58
59
60
61
62
63
64
65

1 the first time in *Knoxdaviesia*, it is a relatively common feature in species of
2 other microascalean genera such as *Scedosporium*, *Petriella* or *Wardomyces*
3 [29, 31], however the role in the nature of the synanamorph is poorly known.
4
5 Another relevant feature of *K. dimorphospora* that it shares with other important
6 human pathogenic species of this group of fungi, such as *L. prolificans* or *S.*
7 *apiospermum*, is the ability to grow at 40 °C. On the contrary, the other two
8 species of *Knoxdaviesia*, i.e. *K. capensis* and *K. proteae*, from which this
9 feature has been evaluated show a maximum temperature for growth at 30°C
10 [32]. Our sequence analysis of the ITS barcode and LSU region of the rDNA
11 has been useful for determining phylogenetic relationships and for establishing
12 species boundaries among *K. dimorphospora* and the currently accepted
13 species of *Knoxdaviesia*, except for distinguishing between *K. capensis* and *K.*
14 *wingfieldii* (Figure 1). In fact, the proposal of the latter species by Roets &
15 Dreyer was based mainly on its morphological differences from *K. capensis*,
16 since their ITS sequences were very similar (99%) [33].
17
18
19
20
21
22
23
24
25
26
27
28
29
30
31
32
33
34
35

36 Olecranon bursitis is the most common and clinically relevant of the
37 superficial bursae due to its predisposition to inflammation and infection given
38 its locations [1, 34]. In fact, the elbow is the most frequent location among the
39 reviewed cases, as it was in our patient, and the infection is usually acquired
40 after traumatic inoculation of the fungus into the skin and subcutaneous tissue
41 (Table 1). Although our patient did not report any direct trauma to the affected
42 area, considering the gardener profession, he had probably become infected by
43 pricking from contaminated plant material. It is of note that most *Knoxdaviesia*
44 species inhabit different trees [14, 32, 35, 36], and despite *K. dimorphospora*
45
46
47
48
49
50
51
52
53
54
55
56
57
58
59
60
61
62
63
64
65

1
2
3
4
5
6
7
8
9
10
11
12
13
14
15
16
17
18
19
20
21
22
23
24
25
26
27
28
29
30
31
32
33
34
35
36
37
38
39
40
41
42
43
44
45
46
47
48
49
50
51
52
53
54
55
56
57
58
59
60
61
62
63
64
65

being described from a human lesion, its natural habitat is probably the same as its counterparts.

Fungal bursitis is treated with oral or parenteral antifungals as well as drainage of infected bursal fluid; which is frequently carried out by needle aspiration. Bursectomy is indicated when there is no response to that treatment, when the bursal fluid cannot be drained or when there is infection of the surrounding soft tissue [1]. Our patient improved quickly after surgical debridement and drainage for 48 h, without receiving any antifungal therapy, probably due to his immunocompetent condition. Most of the cases listed in Table 1 occurred in patients over the age of 50 and about half of them were immunocompromised. The most common treatment reported is the combination of bursal aspiration and/or bursectomy with antifungal therapy, as it is also found in bursal infections by *Candida* species [5] or *S. schenckii* [16]. The drug used for the treatments varies, probably due to the empirical administration or to the result of the *in vitro* antifungal test. Since our patient was infected by a novel species belonging to a genus of Microascales never described, it precludes any type of comparison. However, it is a species susceptible to practically all drugs tested, contrary to the antifungal susceptibility shown by other microascalean fungi of clinical relevance such as *Microascus*, *Scedosporium*, *Scopulariopsis* or *Lomentospora*, which include species with reduced susceptibility or pan resistance to clinically available antifungal drugs [37 - 40].

In summary, the most outstanding facts of the cases reviewed on bursal infection by filamentous fungi is that: 1) coinfection with other microorganisms is not reported, 2) there is a considerable species diversity able to cause this type of infection, 3) the most frequent anatomical site affected was the olecranon

1 followed by prepatellar bursae, and 4) practically all cases were resolved with
2 bursal aspiration or bursectomy and antifungal therapy. In our case, both the
3 presence of fungal elements as well as an important inflammatory reaction
4 observed on the fluid material obtained from the bursa have been key to
5 determining the role of the new fungus, *K. dimorphospora*, as an etiological
6 agent of septic bursitis in an immunocompetent patient. Given the nature of the
7 isolated fungus, we speculate that it might have been acquired by direct trauma
8 with contaminated plant material.
9
10
11
12
13
14
15
16
17
18
19
20
21

22 **Conflict of interest: All authors declare no conflict of interest.**
23
24
25
26
27
28
29
30
31
32
33
34
35
36
37
38
39
40
41
42
43
44
45
46
47
48
49
50
51
52
53
54
55
56
57
58
59
60
61
62
63
64
65

REFERENCES

- 1
2
3
4
5
6
7
8
9
10
11
12
13
14
15
16
17
18
19
20
21
22
23
24
25
26
27
28
29
30
31
32
33
34
35
36
37
38
39
40
41
42
43
44
45
46
47
48
49
50
51
52
53
54
55
56
57
58
59
60
61
62
63
64
65
1. Reilly D, Kamineneni S. Olecranon bursitis. *J Shoulder Elbow Surg.* 2016; 25:158–167.
2. Ornvold K, Paepke J. *Aspergillus terreus* as a cause of septic olecranon bursitis. *Am J Clin Pathol.* 1992; 97:114–116.
3. Del Buono A, Franceschi F, Palumbo A, Denaro V, Maffulli N. Diagnosis and management of olecranon bursitis. *Surgeon.* 2012; 10:297–300.
4. De Hoog GS, Guarro J, Gené J, Figueras MJ. Atlas of clinical fungi. CD-ROM version 3.1. CBS-KNAW Fungal Biodiversity Centre, Utrecht, The Netherlands; 2011.
5. Gamarra-Hilburn CF, Rios G, Vilá LM. Olecranon bursitis caused by *Candida parapsilosis* in a patient with rheumatoid arthritis. *Case Rep Rheumatol.* 2016; *in press* (ID 2019250): 1–5. <http://dx.doi.org/10.1155/2016/2019250>.
6. Burillo A, Moreno A, Salas C. Diagnóstico microbiológico de las infecciones de piel y tejidos blandos. *Enferm Infecc Microbiol Clín.* 2007; 25:579–86.
7. Kornerup A, Wanscher JH. *Methuen handbook of colour.* 3rd ed Eyre Methuen, London; 1978.
8. Figueras MJ, Guarro J. A scanning electron microscopic study of ascoma development in *Chaetomium malaysiense*. *Mycologia.* 1988; 80:298–306.
9. White TJ, Bruns T, Lee S, Taylor JW. Amplification and direct sequencing of fungal ribosomal RNA genes for phylogenetics, p 315–322. In Innis MA, Gelfand DH, Sninsky JJ, White TJ (ed), *PCR protocols: a guide to methods and applications.* Academic Press, New York, NY, USA; 1990.

- 1
2
3
4
5
6
7
8
9
10
11
12
13
14
15
16
17
18
19
20
21
22
23
24
25
26
27
28
29
30
31
32
33
34
35
36
37
38
39
40
41
42
43
44
45
46
47
48
49
50
51
52
53
54
55
56
57
58
59
60
61
62
63
64
65

10. Vilgalys R, Hester M. Rapid genetic identification and mapping of enzymatically amplified ribosomal DNA from several *Cryptococcus* species. *J Bacteriol.* 1990; 172:4238–4246.

11. Tamura K, Stecher G, Peterson D, Filipski A, Kumar S. MEGA6: Molecular Evolutionary Genetics Analysis Version 6.0. *Mol Biol Evol.* 2013; 30:2725–2729.

12. Thompson JD, Higgins DG, Gibson TJ. CLUSTAL W: improving the sensitivity of progressive multiple sequence alignment through sequence weighting, position-specific gap penalties and weight matrix choice. *Nucleic Acids Res.* 1994; 22:4673–4680.

13. Edgar RC. MUSCLE: multiple sequence alignment with high accuracy and high throughput. *Nucleic Acids Res.* 2004; 32:1792–1797.

14. De Beer ZW, Seifert KA, Wingfield MJ. A nomenclator for ophiostomatoid genera and species in the Ophiostomatales and Microascales. *The ophiostomatoid fungi: expanding frontiers.* CBS Biodiversity Series. 2013; 12:245–322.

15. Clinical and Laboratory Standards Institute. Reference method for broth dilution antifungal susceptibility testing of filamentous fungi; approved standard—2nd ed. Document M38-A2. Clinical and Laboratory Standards Institute, Wayne, PA; 2008.

16. Wang JP, Granlund KF, Bozzette SA, Botte MJ, Fierer J. Bursal sporotrichosis: case report and review. *Clin Infect Dis.* 2000; 31:615–616.

17. Torstrick RF, Harrison K, Heckman JD, Johnson JE. Chronic bursitis caused by *Phialophora richardsiae*. *J Bone Joint Surg Am.* 1979; 61:772–774.

- 1
2
3
4
5
6
7
8
9
10
11
12
13
14
15
16
17
18
19
20
21
22
23
24
25
26
27
28
29
30
31
32
33
34
35
36
37
38
39
40
41
42
43
44
45
46
47
48
49
50
51
52
53
54
55
56
57
58
59
60
61
62
63
64
65
18. Westenfeld F, Alston WK, Winn WC. Complicated soft tissue infection with prepatellar bursitis caused by *Paecilomyces lilacinus* in an immunocompetent host: case report and review. *J Clin Microbiol.* 1996; 34:1559–1562.
 19. Cornia PB, Raugi GJ, Miller RA. *Phialophora richardsiae* bursitis treated medically. *Am J Med.* 2003; 115:77–79.
 20. Wessolossky M, Haran JP, Bagchi K. *Paecilomyces lilacinus* olecranon bursitis in an immunocompromised host: case report and review. *Diagn Microbiol Infect Dis.* 2008; 61:354–357.
 21. Levenstadt JS, Poutanen SM, Mohan S, Zhang S, Silverman M. *Pleurostomophora richardsiae*—an insidious fungus presenting in a man 44 years after initial inoculation: A case report and review of the literature. *Can J Infect Dis.* 2012; 23:110.
 22. Gertner E. Chronic septic bursitis caused by dematiaceous fungi. *Am J Orthop* 36:E10–E11; 2007.
 23. Bossler AD, Richter SS, Chavez AJ, et al. *Exophiala oligosperma* causing olecranon bursitis. *J Clin Microbiol.* 2003; 41:4779–4782.
 24. Kwon-Chung KJ, Droller DD. Infection of the olecranon bursa by *Anthopsis deltoidea*. *J Clin Microbiol.* 1984; 20:271–273.
 25. Cariello PF, Wickes BL, Sutton DA, et al. *Phomopsis bougainvilleicola* prepatellar bursitis in a renal transplant recipient. *J Clin Microbiol.* 2013; 51:692–695.
 26. Berger RG. Chronic fungal olecranon bursitis caused by *Penicillium*. *Arthritis Rheum.* 1989; 32:239–240.

- 1
2
3
4
5
6
7
8
9
10
11
12
13
14
15
16
17
18
19
20
21
22
23
24
25
26
27
28
29
30
31
32
33
34
35
36
37
38
39
40
41
42
43
44
45
46
47
48
49
50
51
52
53
54
55
56
57
58
59
60
61
62
63
64
65
27. Llinas L, Olenginski TP, Bush D, Gotoff R, Weber V. Osteomyelitis resulting from chronic filamentous fungus olecranon bursitis. *J Clin Rheumatol*. 2005; 11:280–282.
 28. Sadigursky D, e Ferreira LN, de Oliveira Corrêa LM. Phaeohyphomycosis infection in the knee. *Rev Bras Ortop*. 2016; 51:231–234.
 29. Lackner M, de Hoog GS, Yang L, et al. Proposed nomenclature for *Pseudallescheria*, *Scedosporium* and related genera. *Fungal Diversity*. 2014; 67:1–10.
 30. Wingfield BD, Viljoen CD, Wingfield MJ. Phylogenetic relationships of ophiostomatoid fungi associated with *Protea* infructescences in South Africa. *Mycol Res*. 1999; 103:1616–1620.
 31. Sandoval-Denis M, Guarro J, Cano-Lira JF, et al. 2016. Phylogeny and taxonomic revision of *Microascaceae* with emphasis on synnematosus fungi. *Stud Mycol* 83:193–233.
 32. Aylward J, Dreyer LL, Steenkamp ET, Wingfield MJ, Roets F. *Knoxdaviesia proteae* is not the only *Knoxdaviesia*-symbiont of *Protea repens*. *IMA Fungus*. 2015; 6:471–476.
 33. Crous PW, Summerell BA, Shivas RG, et al. Fungal Planet description sheets: 107–127. *Persoonia*. 2012; 28:138–182.
 34. Khodae M. Common superficial bursitis. *Am Fam Physician*. 2017; 95:224–231.
 35. Kolařík M, Hulcr J. Mycobiota associated with the ambrosia beetle *Scolytodes unipunctatus* (Coleoptera: Curculionidae, Scolytinae). *Mycol Res*. 2009; 113:44–60.

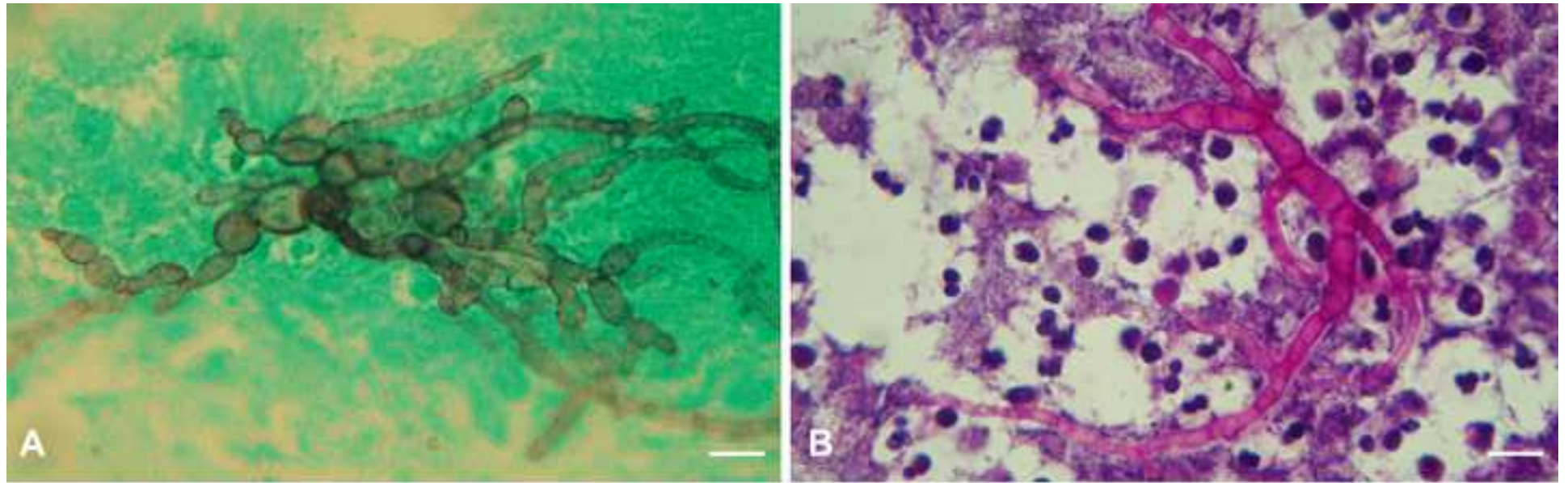
- 1
2
3
4
5
6
7
8
9
10
11
12
13
14
15
16
17
18
19
20
21
22
23
24
25
26
27
28
29
30
31
32
33
34
35
36
37
38
39
40
41
42
43
44
45
46
47
48
49
50
51
52
53
54
55
56
57
58
59
60
61
62
63
64
65
36. Van der Linde JA, Six DL, Wingfield MJ, Roux J. New species of *Gondwanamyces* from dying Euphorbia trees in South Africa. *Mycologia*. 2012; 104:574–584.
 37. Gilgado F, Serena C, Cano J, Gené J, Guarro J. Antifungal susceptibilities of the species of the *Pseudallescheria boydii* complex. *Antimicrob Agents Chemother*. 2006; 50:4211–4213.
 38. Iwen PC, Schutte SD, Florescu DF, Noel-Hurst RK, Sigler L. Invasive *Scopulariopsis brevicaulis* infection in an immunocompromised patient and review of prior cases caused by *Scopulariopsis* and *Microascus* species. *Med Mycol*. 2012; 50:561–569.
 39. Sandoval-Denis M, Sutton DA, Fothergill AW, et al. *Scopulariopsis*, a poorly known opportunistic fungus: spectrum of species in clinical samples and *in vitro* responses to antifungal drugs. *J Clin Microbiol*. 2013; 51:3937–3943.
 40. Wiederhold NP. Antifungal resistance: current trends and future strategies to combat. *Infect Drug Resist*. 2017; 10:249–259.

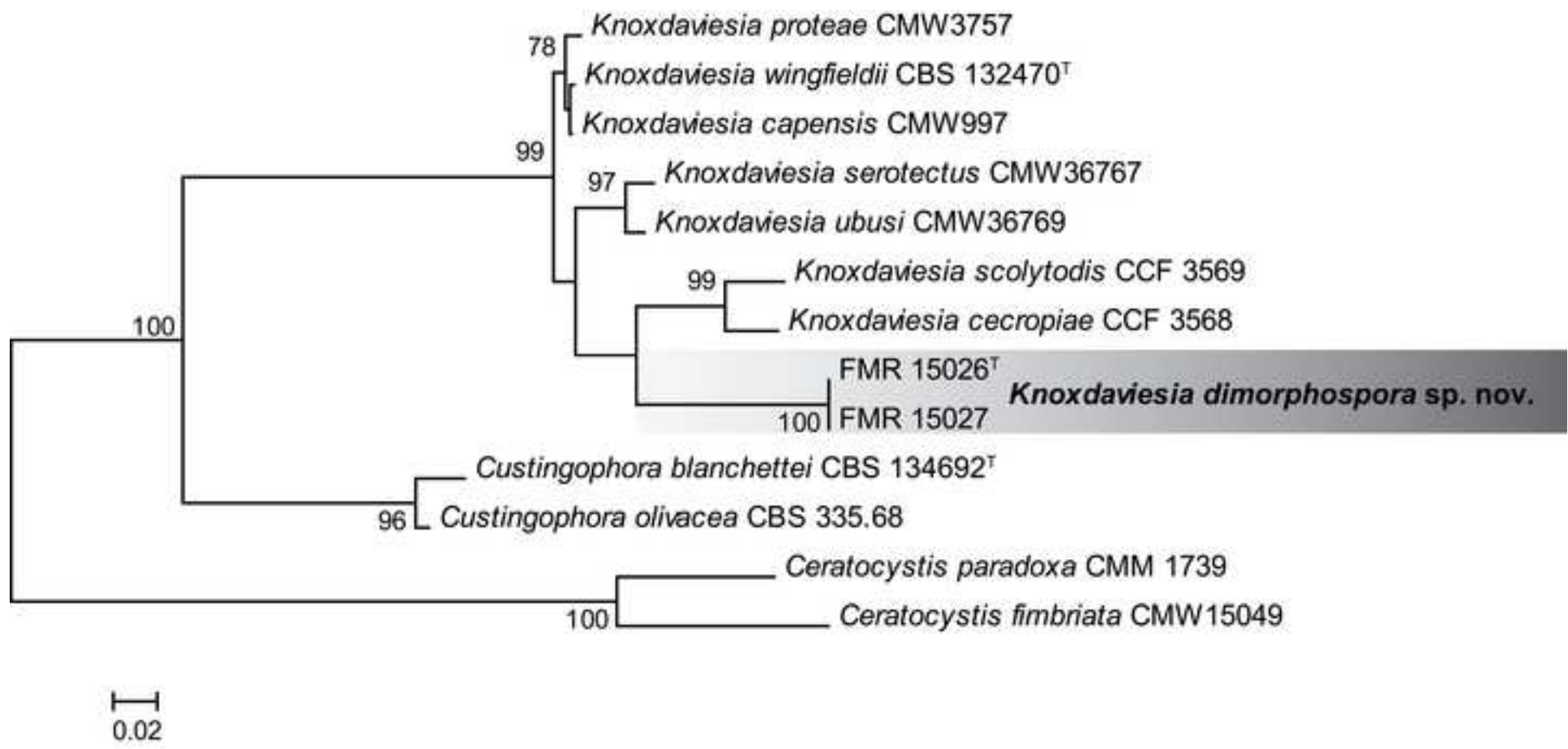
1
2
3
4
5
6
7
8
9
10
11
12
13
14
15
16
17
18
19
20
21
22
23
24
25
26
27
28
29
30
31
32
33
34
35
36
37
38
39
40
41
42
43
44
45
46
47
48
49
50
51
52
53
54
55
56
57
58
59
60
61
62
63
64
65

Figure 1. (A, B) *Knoxdaviesia dimorphospora* in debridement fluid samples from the olecranon bursa. (A) Grocott's silver methenamine stain revealing the presence of septate, branched and pigmented hyphae. (B) PAS stain showing hyphae in the midst of abundant inflammatory cells. Scale bars = 10 μ m.

Figure 2. Maximum-likelihood (ML) tree constructed with the combination of ITS (606 bp) and LSU (781 bp) sequence data available from the species of *Knoxdaviesia* genus. Bootstrap support values above 70% are indicated at the nodes. The phylogenetic tree was constructed with species of closely related genera: *Custingophora* and *Ceratocystis*. T: type strain. The new species proposed is shown in the dark box.

Figure 3. (A-N) *Knoxdaviesia dimorphospora*, ex-type FMR 15026. (A) Colonies growing on PCA, MEA, PDA and OA after 7 d at 25 °C. (B-E) Conidiophores, F-H. Foot cells with rhizoids, I.-J Conidia. (K-N) Conidiogenous cells and conidia of the synanamorph. Scale bars = 10 μ m.





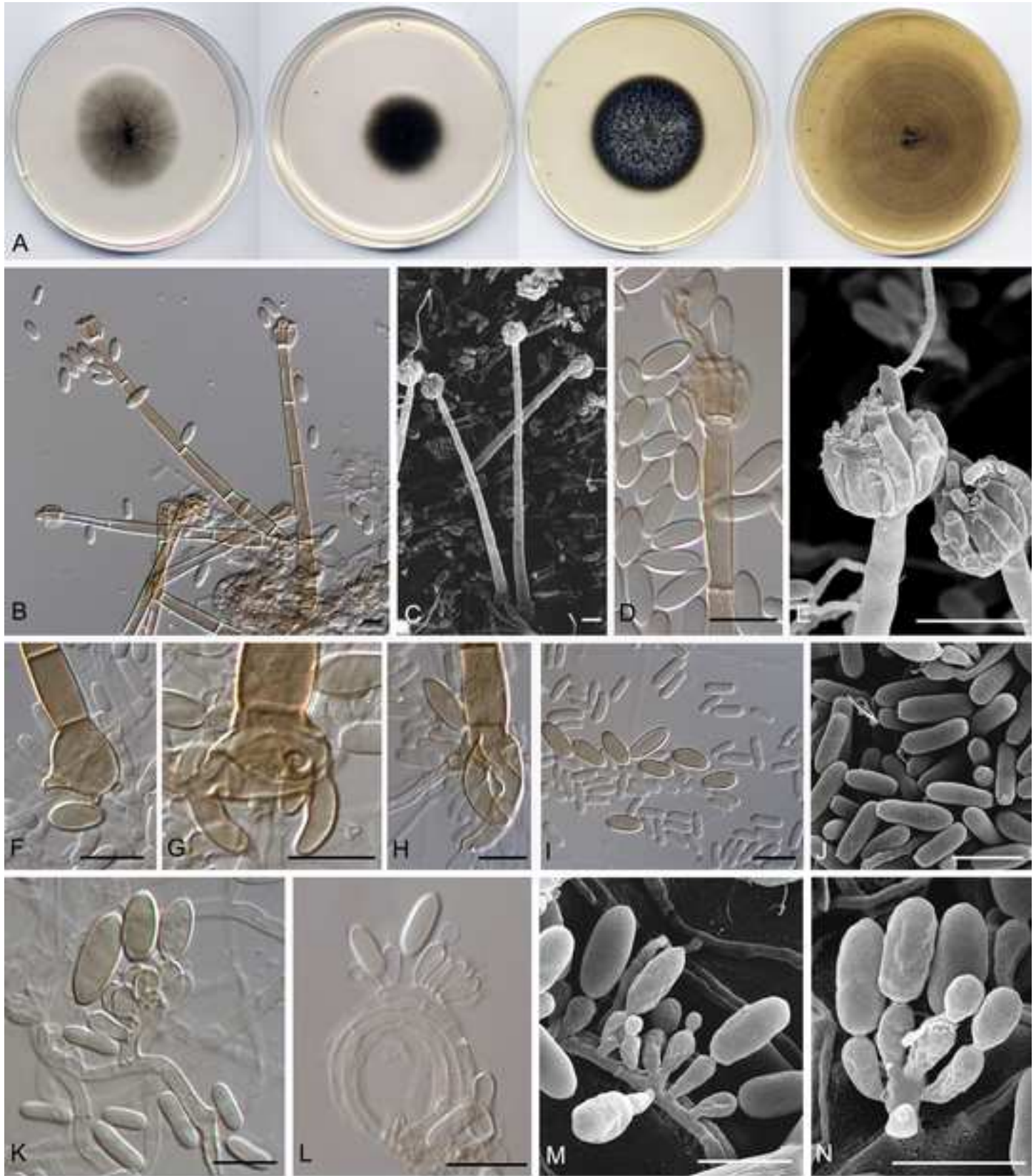


Table 1. Clinical cases of septic bursitis caused by filamentous fungi different to *Sporothrix schenckii*. [16]

Species involved	Age/sex	Infected bursa	Comorbidities	Other risk factors	Co-infection	Treatment	Reference
<i>Anthopsis deltoidea</i>	79/M	Right olecranon	Prostatic carcinoma	Corticosteroids	Negative	Bursectomy, flucytosine	[24]
<i>Aspergillus terreus</i>	72/M	Right olecranon	Non-insulin-dependent diabetic	Trauma	Negative	Bursectomy	[2]
<i>Exophiala oligosperma</i>	62/M	Left olecranon	Wegener's granulomatosis, immunosuppressive therapy	Corticosteroids, trauma	Negative	Aspiration of bursal fluid, amphotericin B	[23]
<i>Fonsecaea pedrosoi</i>	65/F	Left olecranon	None	Trauma	Negative	Aspiration of bursal fluid	[22]
<i>Knoxdaviesia dimorphospora</i>	46/M	Left olecranon	None	None	Negative	Surgically debrided, drainage	Current case
<i>Phaeoacremonium</i> sp.	54/F	Right olecranon	Myelodysplastic syndrome	Trauma	Negative	Bursectomy, itraconazole	[27]
<i>Phomopsis bougainvilleicola</i>	61/M	Right knee	Chronic renal disease	Corticosteroids, kidney transplant	Negative	Aspiration of bursal fluid, voriconazole	[25]
<i>Purpureocillium lilacinum</i> (as <i>Paecilomyces lilacinus</i>)	35/M	Right knee	None	None	Negative	Aspiration of bursal fluid, fluconazole, miconazole, ketoconazole.	[18]
<i>Purpureocillium lilacinum</i>	86/M	Left olecranon	Chronic lymphocytic leukemia	Secondary common variable immunodeficiency with intravenous immunoglobulin	Negative	Aspiration of bursal fluid, fluconazole, ketoconazole, bursectomy	[20]
<i>Pleurostomophora richardsiae</i> (as <i>Phialophora richardsiae</i>)	79/M	Right shoulder	None	Trauma	Negative	Bursectomy, cephalexin	[17]
<i>Pleurostomophora richardsiae</i>	77/M	Right knee	None	None	Negative	Aspiration of bursal fluid, amphotericin B	[19]
<i>Pleurostomophora richardsiae</i>	54/M	Right prepatellar	None	Trauma	Negative	Patient refused treatment	[21]
<i>Penicillium</i> sp.	76/F	Right olecranon	Asthma, congestive heart failure, deep vein thrombosis, adenocarcinoma of the colon	Corticosteroids, trauma	Negative	Surgically debrided, ketakonazole	[26]
Dematiaceous mold (Unknown)	76/M	Left olecranon	None	None	Negative	Bursectomy, itraconazole	[28]

M=male; F=female