

Accepted Manuscript

Title: Daylight photodynamic therapy using methylene blue to treat sheep with dermatophytosis caused by *Arthroderma vanbreuseghemii*



Authors: Vanesa Pérez-Laguna, Antonio Rezusta, Juan José Ramos, Luís Miguel Ferrer, Josepa Gené, María José Reville, Yolanda Gilaberte

PII: S0921-4488(17)30079-2
DOI: <http://dx.doi.org/doi:10.1016/j.smallrumres.2017.03.011>
Reference: RUMIN 5449

To appear in: *Small Ruminant Research*

Received date: 6-10-2016
Revised date: 7-3-2017
Accepted date: 11-3-2017

Please cite this article as: <http://dx.doi.org/>

This is a PDF file of an unedited manuscript that has been accepted for publication. As a service to our customers we are providing this early version of the manuscript. The manuscript will undergo copyediting, typesetting, and review of the resulting proof before it is published in its final form. Please note that during the production process errors may be discovered which could affect the content, and all legal disclaimers that apply to the journal pertain.

Short communication:

Daylight photodynamic therapy using methylene blue to treat sheep with dermatophytosis caused by *Arthroderma vanbreuseghemii*

Authors and affiliations:

Vanesa Pérez-Laguna¹, Antonio Rezusta^{1, 2, 3}, Juan José Ramos⁴, Luís Miguel Ferrer⁴, Josepa Gené⁵, María José Revillo^{1, 2}, Yolanda Gilaberte^{2, 6}.

(1) Department of Microbiology, Miguel Servet University Hospital. Zaragoza, Spain.

(2) IIS Aragón. Zaragoza, Spain

(3) Department of Microbiology, Preventive Medicine and Public Health. Zaragoza University. Zaragoza, Spain. 18

(4) Department of Animal Pathology. Veterinary Faculty. Zaragoza University. Zaragoza, Spain.

(5) Microbiology Unit, Medical School, Universitat Rovira i Virgili, IISPV. Reus, Spain.

(6) Department of Dermatology. San Jorge Hospital. Huesca, Spain.

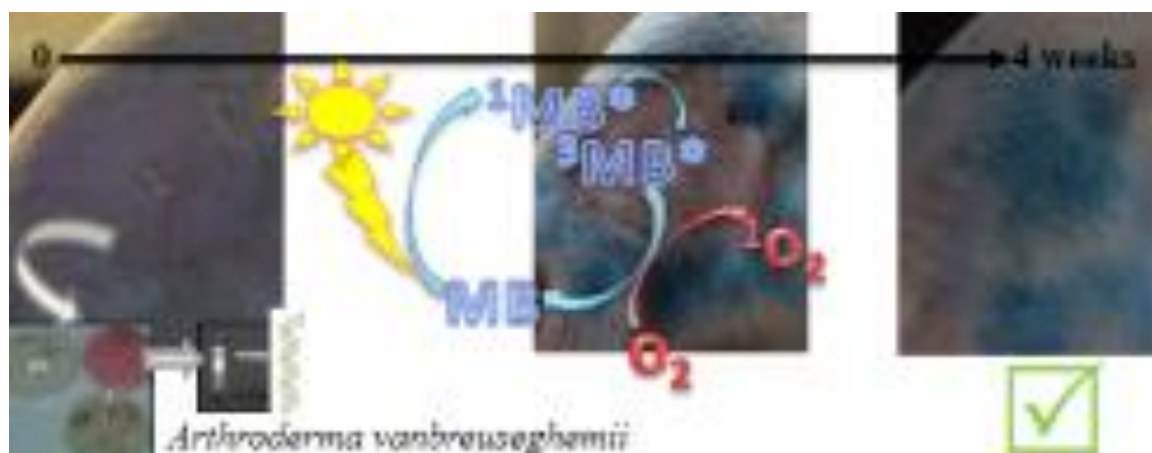
Complete correspondence address:

Vanesa Pérez-Laguna

Department of Microbiology, Miguel Servet University Hospital. C/ Padre Arrupe s/n 50009 Zaragoza, Spain

E-mail: 565686@unizar.es

Graphical abstract



Highlights

- *Arthroderma vanbreuseghemii* was identified as the causative agent of dermatophytosis in a flock of sheep.
- Antimicrobial daylight photodynamic therapy (aDL-PDT) using 1% methylene blue solution was tested.
- aDL-PDT seems to be effective, safe and efficient to treat dermatophytosis in sheep.

Abstract

Arthroderma vanbreuseghemii has been identified molecularly as the causative agent of dermatophytosis in a flock of sheep. It is necessary to explore new treatment alternatives because antifungals are not approved for use on small ruminant animals in the European Union. Antimicrobial photodynamic therapy (aPDT) has been shown to be effective for the treatment of dermatophytosis in humans. It is based on the application of a photosensitizer such as methylene blue (MB) that is activated by visible light to generate reactive oxygen

species that are cytotoxic to cells. The use of daylight to perform aPDT (aDL-PDT) avoids the requirement of specific equipment because it uses sunlight to activate the photosensitizer. The aim of our study is to determine the efficacy of aDL-PDT using a 1% MB solution to treat dermatophytosis caused by *A. vanbreuseghemii* in ewes. Two different topical protocols (1% MB solution spray applications once or twice a week) were assayed in two groups of five infected animals. Twenty-five infected sheep were untreated. All the sheep were exposed to sunlight every day for an approximate duration of 10 hours for a total of four weeks. At the end of the study, all the animals treated with aDL-PDT showed the same clinical response to both protocols. In contrast, the animals exposed only to sunlight required an additional two to four weeks before their infections resolved.

Conclusion: aDL-PDT with 1% MB solution demonstrates efficacy, safety and efficiency in the treatment of dermatophytosis in sheep.

Keywords: Tinea / Ringworm; *Trichophyton* spp.; Photoinactivation; photodynamic therapy

1. Introduction

Dermatophytosis (tinea or ringworm) is a skin disease caused by keratinophilic fungi belonging to the family *Arthrodermataceae* that includes genera *Trichophyton*, *Microsporum* and *Epidermophyton* (Borman and Summerbell, 2015). These generic names are historically applied to the asexual state of the fungi, and any dermatophyte capable of sexual reproduction also has historical teleomorph names in the genus *Arthroderma* (Weitzman et al. 1986). In domestic ruminants, dermatophytosis is nearly exclusively caused by *Trichophyton* spp. (Rochette et al. 2003). The clinical signs are usually mild and active lesions which heal after 6 to 16 weeks (Roberson et al. 2012) (Borman and Summerbell, 2015). However,

dermatophytosis is present worldwide in cattle and sheep and can cause high economic losses in farms, is highly contagious and can have an impact on public health when a zoonotic mycotic species is involved (Rochette et al. 2003).

We confirmed our diagnosis of dermatophytosis by isolating *A. vanbreuseghemii* in a culture. A presumptive diagnosis based on clinical signs and history is also generally acceptable because fungal contaminants and secondary bacterial infections often contaminate cultures (Borman and Summerbell, 2015).

The most significant obstacle in the treatment of dermatophytosis is that specific antimycotic treatments, such as griseofulvin because of its accumulation in tissues and teratogenic effects, are banned from use in sheep and other food-producing animals in the European Community. Furthermore, topical treatments such as iodine 5% are not usually used because they dye the wool, last long, and their application is complicated. Enilconazole's topical application is permitted in cattle, but is not approved for sheep.

Photodynamic Therapy (PDT) is a technique that utilizes the reactive oxygen species (ROS) produced by non-toxic dye or photosensitizer (PS) molecules in the presence of visible light to destroy target cells (Buchholz and Walt. 2013). It was originally developed for the treatment of cancer, but it has been successfully employed in the treatment of infectious diseases, including fungal infections (Lyon et al. 2011) (Buchholz and Walt. 2013). However, the specific equipment required to perform the illuminations makes the therapy too complicated and expensive to be used in clinical veterinary. Daylight PDT (DL-PDT) is a new modality of PDT that uses sunlight to activate the PS instead of lamps. It has been shown to be as effective as conventional PDT in treating actinic keratosis using methyl-aminolevulinate (MAL) as PS (Morton et al 2015). The use of daylight simplifies the PDT-procedure, makes it more efficient, (Wiegell et al.2012) and makes it possible to utilize for the treatment of animals, especially for superficial cutaneous infections.

Methylene blue (MB), a well-known dye with a high ability to generate $^1\text{O}_2$, has shown photodynamic activity against several infections, including dermatophytosis (Souza et al. 2014).

The aim of our study is to investigate the efficacy of MB-DL-PDT to treat dermatophytosis in sheep.

2. Material and Methods

2.1. *Type of study and farm characteristics*

We conducted an experimental, controlled trial, on a privately owned flock of domestic sheep. We used clinical practice methods in our study, prioritised interfering only minimally with flock management, and took care not to cause additional stress to the animals. The farm is located in the province of Zaragoza, Spain. The animals were kept in communal yards with uncovered areas, and without any supplementary light. At night, the sheep were housed in pens with adequate indoor and outdoor space. The flock had no history of antifungal or antibacterial therapy during the months preceding our trial.

2.2. *Study group*

A total of 35 replacement ewe lambs clinically diagnosed with dermatophytosis were included in the study. All the lambs presented with scaling, crusts, annular plaques, and hair loss. The main clinical, dermatological patterns were those of non-pruritic, exfoliative dermatitis with focal-multifocal alopecias. The selected infected lambs were divided in two groups. One group of 10 ewes with 14 active lesions was selected for treatment application. The other group of 25 infected animals was not treated and was used as the control group.

2.3. *Specimen collection, microscopy examination and culture*

We discovered that the lesion samples taken from the first sheep included in our study were systematically contaminated, but we could not identify the etiological agent. Therefore, for all

subsequent samples, the area was cleaned with 70% alcohol, and the first scraping was discarded. We collected hair, wool, and skin scrapings from the 10 infected ruminants in the treatment group in this manner. The advancing border of the lesion was scraped with the blunt edge of a sterile, disposable scalpel; hairs and scales were plucked with sterile tweezers; dry and sterile containers were used for sample transport.

The hair plucking, skin scrapings, and coat brushings were treated with KOH 20 % mixed with equal parts of Calcofluor-white (Robinson and Padhye, 1988) (Borman and Summerbell, 2015) for direct microscopy examination. The skin scrapings were cultured on Sabouraud dextrose agar medium with chloramphenicol, (Oxoid, Basic stock, UK) dermatophyte test medium containing cycloheximide, (Oxoid, Basic stock, UK) and potato dextrose agar (Oxoid, Basic stock, UK) with of 50 mg/L chloramphenicol.

2.4. Molecular identification

To confirm laboratory diagnosis, a sequence-based identification was performed for two representative isolates, FMR 14361 (= 6334 - TA) and FMR 14362, (= 6455 - TA) from different animal specimens selected at random because all the samples seemed to be the same macroscopically and microscopically.

The total genomic DNA was extracted from fresh mycelia harvested from colonies grown on the PDA for seven days at 25°C using the FastPrep kit (MP Biomedicals, Santa Ana, CA) according to the manufacturer's protocol. The DNA was quantified using a Nanodrop 3000 apparatus (Thermo Scientific, Madrid, Spain). A region spanning the internal transcribed spacer 1 (ITS1) and ITS2 and the 5.8 S gene of the ribosomal DNA (rDNA) was amplified using the primer pairs ITS4 and ITS5 (White et al., 1990). The amplified products were purified with the Diffinity RapidTip purification system (Sigma-Aldrich, St. Louis, MO) and stored at -20°C until sequencing. The sequencing was performed in both directions, with the same primer pair as used for amplification, at MacroGen Europe (MacroGen Inc., Amsterdam,

The Netherlands). The consensus sequences were obtained using SeqMan version 7.0.0 (DNASStar Lasergene, Madison, WI).

The obtained sequences were compared for identity against reference sequence materials available in several public databases i.e., NCBI BLAST (www.ncbi.nlm.nih.gov), the ISHAM database (<http://its.mycologylab.org>), and the CBS Pairwise sequence alignment database (www.cbs.knaw.nl).

2.5. Clinical treatment protocols

Stock MB (Sigma-Aldrich Corporation, Steinheim, Germany) solution was prepared in distilled water and diluted with bidistilled water to the desired concentration 1:100 MB (10 g dissolved in one litre of water, sterilization at 121 °C). The solutions were prepared and handled under light-restricted conditions.

A solution of MB 1% was sprayed on the fourteen lesions of the infected sheep of the treatment group for a total of four weeks. These lesions were completely covered in MB, seven of them once, and seven lesions twice a week. Prior to MB application, three lesions from the former treatment group (once a week) were cleaned by removing skin scales with a scalpel blade before applying the MB, whereas on the remaining four lesions, the MB was sprayed directly. We also followed this protocol for the twice a week group. After MB application, the sheep were exposed to direct sun all morning and part of the afternoon, approximately 10 hours a day. The 25 ewes of the control group were exposed to the same protocol except the MB application.

The primary efficacy end point was the clinical improvement, monitored through photographs taken twice a week. The whole farm was under surveillance during a follow-up period of 10 weeks.

3. Results

Seven samples taken from the 10 sheep selected to test the treatment with MB-aDL-PDT proved positive (fungal growth) through plate culture, and six samples were positive (visualization of fungi) through direct microscopic examination prior to treatment when we were verifying the pathogen. Our results are shown in Table 1. The causal agent observed was *A. vanbreuseghemii*. It was determined through plate culture, as well as direct microscopic examination from samples taken from four ewes. The samples from the SN-2 TA sheep were the only double negative. The negative samples were retained for four weeks before we discarded them as negative. The isolates 6334 TA and 6455 TA *A. vanbreuseghemii* were selected from the cultures and identified by molecular techniques.

The analysis of the ITS sequences of the two isolates, FMR 14361 (= 6334 TA) and FMR 14362 (= 6455 TA), yielded high degrees of identity (>99%) and coverage, (>99%) with several reference sequences of *A. vanbreuseghemii* including the type strain of its anamorph, *Trichophyton interdigitale* CBS 428.63 (GenBank sequence accession number JX122216). Thus, we conclude that it is unambiguously assigned to this species. The numbers of the two dermatophyte strain sequences deposited in GenBank are KT963002 for FMR 14361 (=6334TA) and KT963003 for FMR 14362 (=6455 TA).

The 14 treated skin lesions of the 10 animals gradually improved during the period of MB-aDL-PDT application, and hair regrowth started (Figure 1). No relapse of the disease was observed during a follow-up period of ten weeks, and no adverse effects were observed at any time. No differences were detected from applying the PS once or twice a week (Figure 2). Cleaning the lesions before the spray application of the PS did not affect the efficacy of the treatment.

All the sheep from the control group took between six to eight weeks to reach complete clinical resolution, which was two to four weeks more than the group treated with aDL-PDT

4. Discussion

Our study demonstrates the efficacy of aDL-PDT using 1% MB solution for the treatment of dermatophytosis in ewes caused by *A. vanbreuseghemii*. The results obtained after four weeks of treatment are promising; the skin lesions showed a significant reduction upon physical examination after two weeks. Thereby, according to our results, one application a week for four weeks, or possibly two weeks, would be an adequate therapeutic dose because there were no differences between sheep treated once or twice a week.

The differential diagnosis of dermatophytosis in ewes has to be performed when other skin diseases are suspected, especially scabies, urticaria, bacterial and viral infections (e.g. staphylococcal folliculitis or contagious viral pustular dermatitis), seborrheic dermatitis, and zinc-responsive dermatitis. Clinical suspicion is enough to start the treatment because microbiological diagnosis is difficult due to the enormous amounts of saprophytes and opportunistic agents, especially fungal spores and conidia, and bacteria present on the skin of the sheep. Therefore, samples must be taken from the edges lesions after cleaning the area and removing the first flakes of skin. We discovered that we had to change our initial sampling methodology in order to avoid contaminants. For isolation cultures, the addition of antibacterial substances and cycloheximide to the medium in order to inhibit the growth of contaminating fungi, is highly recommended (Borman and Summerbell, 2015). Two diagnostic laboratories are involved in our study, and in only one of them that has ISO 15189 and used media with inhibitory selective substances, the causative agent was isolated. It is possible that dermatophyte infections are difficult to diagnose because the fungi are relatively protected within hair shafts and hair follicles (Borman and Summerbell, 2015).

The isolates did not produce conidia, which makes morphological identification impossible; therefore, molecular identification is helpful. The PCR amplification and sequencing of ITS-1

has proven effective for dermatophyte identification (Li et al. 2008). The recommendation of standard DNA barcodes (Summerbell 2007) is in progress, and the ITS-1 region is emerging as a key panfungal region for the molecular identification of moulds, including dermatophytes (Balajee 2008, Li et al. 2008).

With regard to the molecular identification of the causative agent *A. vanbreuseghemii*, to our knowledge, this is the first confirmed case of this kind of infection in sheep. This is probably due to the fact that it can be confused with other zoophilic species with similar clinical manifestations, and when it is isolated in culture, it is often misidentified due to its phenotypical similarity with *T. verrucosum*.

To objectively assess the efficacy and effectiveness of the MB, we should compare it with the progression of the infection without treatment, and with the standard treatment of ringworm, even though there is no specific treatment protocol for small ruminants. The untreated sheep usually self-heal, (Roberson et al. 2012) (Borman and Summerbell, 2015) although the duration of healing is longer, about two to four weeks longer, than for those animals treated with aDL-PDT. With respect to antifungals, enilconazole should also be applied topically, with a frequency range of once a week to three times per week, depending on the severity of the lesions. The treatment duration is usually two weeks, and the lesions start improving between two and four weeks after the last application, depending on the severity of the lesions (Rochette et al. 2003). Conventional treatment therefore, may require more applications, and the lesions do not improve in less time than with aDL-PDT. Furthermore, MB is not associated with residue risks, and its blue stain on the skin, hair and wool completely disappeared after the therapy concluded. This fact is very important because sheep are used for meat and they are subject to strict controls against residues to avoid health risks.

Different PSs have been shown to effectively photoinactivate different genera of dermatophytes such as hypericin (Paz-Cristobal et al. 2014) and Toluidine Blue O *in vitro*

(Mehra et al. 2015). PDT with MAL has been successfully employed against superficial fungal infections in humans, including dermatophytoses, in several clinical studies (Lyon et al. 2011) (Gilaberte et al. 2011). Recently, Souza et al. demonstrated the efficacy of PDT using 2% MB to treat severe distal and lateral subungual toenail onychomycosis (Souza 2014). However, to our knowledge, there are neither studies using MB-PDT to treat dermatophyte infections in animals—it has been only explored in cases of bovine mastitis, (Sellera et al. 2016a) and in cases of caseous lymphadenitis abscesses in sheep (Sellera et al. 2016b)—nor studies exploring the efficacy of aDL-PDT using MB in humans or in animals. Furthermore, the use of MB-aDL-PDT to treat ringworm in sheep is of note because it is effective and safe for humans, as well as inexpensive and easy to apply on sheep which are usually exposed to sunlight.

Some of the limitations of our study are (1) the sample size was small and therefore our results should be confirmed in larger studies; (2) we did not have another control group exposed only to MB; therefore, the effect of MB without the catalyst of sunlight on healing ringworms could not be excluded. We also did not have a group of healthy ewes treated with MB; and (3) microbiological samples were not taken from the control group; they were only subjected to the clinical follow up, and their microbiological cure was not confirmed for the MB groups.

5. Conclusion

In our study, *A. vanbreuseghemii* was identified as a causative agent of dermatophytosis in a flock of sheep. According to our results, MB-aDL-PDT could be a promising treatment for ringworm, especially in those cases caused by this agent. Whether this treatment can be used in veterinary clinics, or for other kinds of superficial infections, or on other species of animals is yet to be determined.

Conflict of interest

None of the authors have any conflict of interest

Acknowledgements

This work was supported by grant CTQ2013-48767-C3-2-R from the Spanish Ministerio de Economía y Competitividad.

We the authors thank the owners of the sheep for trusting us to treat their flock.

References

- Balajee, S.A., Borman, A.M., Brandt, M.E., Cano, J., Cuenca-Estrella, M., Dannaoui, E., Guarro, J., Haase, G., Kibbler, C.C., Meyer, W., O'Donnell, K., Petti, C.A., Rodriguez-Tudela, J.L., Sutton, D., Velegraki, A., Wickes, B.L., 2009. Sequence-based identification of *Aspergillus*, *fusarium*, and *mucorales* species in the clinical mycology laboratory: where are we and where should we go from here? *J Clin Microbiol.* 47(4), 877-84.
- Borman, A.M. and Summerbell, R.C., 2015. Chapter 123: Trichophyton, Microsporum, Epidermophyton, and Agents of Superficial Mycoses. In: *Manual of Clinical Microbiology*, 11th Edition. Vol. 2. American Society for Microbiology (ASM). pp 2128-2152.
- Buchholz, J., Walt, H., 2013. Veterinary photodynamic therapy: A review. *Photodiagnosis Photodyn. Ther.* 10, 342–347.

- Gilaberte, Y., Aspiroz, C., Martes, M.P., Alcalde, V., Espinel-Ingroff, A., Rezusta, A., 2011. Treatment of refractory fingernail onychomycosis caused by non-dermatophyte moulds with methylaminolevulinate photodynamic therapy. *J Am Acad Dermatol.* 65, 669-671.
- Li, H.C., Bouchara, J.P., Hsu, M.M., Barton, R., Su, S., Chang, T.C., 2008. Identification of dermatophytes by sequence analysis of the rRNA gene internal transcribed spacer regions. *J Med Microbiol.* 57(Pt 5), 592-600.
- Lyon, J.P., Moreira, L.M., Moraes, P.C.G., Santos, F.V., Resende, M.A., 2011. Photodynamic therapy for pathogenic fungi. *Mycoses.* 54, E265-71.
- Mehra, T., Schaller, M., Walker, B., Braunsdorf, C., Mailänder-Sanchez, D., Schynowski, F., Hahn, R., Röcken, M., Köberle, M., Borelli, C., 2015. Efficacy of antifungal PACT in an in vitro model of onychomycosis. *J Eur Acad Dermatol Venereol.* 29(1), 86-90.
- Morton, C.A., Wulf, H.C., Szeimies, R.M., Gilaberte, Y., Basset-Seguín, N., Sotiriou, E., Piaserico, S., Hunger, R.E., Baharlou, S., Sidoroff, A., Braathen, L.R., 2015. Practical approach to the use of daylight photodynamic therapy with topical methyl aminolevulinate for actinic keratosis: a European consensus. *J Eur Acad Dermatol Venereol.* 29(9):1718-23
- Paz-Cristobal, M. P., Gilaberte, Y., Alejandre, C., Pardo, J., Revillo, M.J., Rezusta, A., 2014. In vitro fungicidal photodynamic effect of hypericin on *Trichophyton* spp. *Mycopathologia.* 178(3-4):221-5.
- Roberson, J.R., Baird, A.N., Pugh, D.G., 2012. Chapter 10: Diseases of the Integumentary System. In: *Sheep and Goat Medicine.* 2^a edición Ed: Elsevier Saunders, pp. 256-290
- Robinson, B. E., and Padhye A. A., 1988. Collection transport and processing of clinical specimens. In: Wentworth B. B. (ed.), *Diagnostic Procedures for Mycotic and Parasitic Infections*, 7th ed. American Public Health Association, Inc., Washington, DC., pp. 11-32.
- Rochette, F., Engelen, M., Vanden Bossche, H. 2003. Antifungal agents of use in animal health – practical applications. *J. Vet. Pharmacol. Therap.* 26, 31–53.

Sellera F.P., Sabino C.P., Ribeiro, M.S. Gargano R.G., Benites N.R., Melville P.A., Pogliani F.C., 2016b. In vitro photoinactivation of bovine mastitis related pathogens, *Photodiagnosis Photodyn. Ther.* 13, 276-81.

Sellera, F.P., Gargano, R.G., Libera, A.M., Benesi, F.J., Azedo, M.R., de Sá, L.R., Ribeiro, M.S., da Silva Baptista, M., Pogliani, F.C., 2016a. Antimicrobial photodynamic therapy for caseous lymphadenitis abscesses in sheep: Report of ten cases. *Photodiagnosis Photodyn Ther.* 13, 120-2.

Souza, L.W.F., Souza, S.V.T., Botelho, A.C. de C., 2014. Distal and lateral toenail onychomycosis caused by *Trichophyton rubrum*: treatment with photodynamic therapy based on methylene blue dye. *An. Bras. Dermatol.* 89, 184-186

Summerbell, R.C., Moore, M.K., Starrink-Willemse, M., Van Iperen, A., 2007. ITS barcodes for *Trichophyton tonsurans* and *T. equinum*. *Med Mycol.* 45, 193-200

Weitzman, I., McGinnis, M.R., Padhye, A.A., Ajello, L., 1986. The genus *Arthroderma* and its later synonym *Nannizzia*. *Mycotaxon* 25, 505-518.

White, T. J., Bruns, T., Lee, S., Taylor, J., 1990. Amplification and direct sequencing of fungal ribosomal RNA genes for phylogenetics. *PCR Protocols: A guide to Methods and Applications* (ed. M. A. Innis, D. H. Gelfand, J. J. Sninsky & T. J. White), pp. 315±322. Academic Press : San Diego, U.S.A.

Wiegell, S.R., Wulf, H.C., Szeimies, R.M., Basset-Seguín, N., Bissonnette, R., Gerritsen, M.J., Gilaberte, Y., Calzavara-Pinton, P., Morton, C.A., Sidoroff, A., Braathen, L.R., 2012. Daylight photodynamic therapy for actinic keratosis: an international consensus: International Society for Photodynamic Therapy in Dermatology. *J Eur Acad Dermatol Venereol.* 26(6), 673-9.

Figure 1: Progress of the lesions in the 6036 –TA sheep. Clinical treatment protocol: the lesion was completely covered in MB twice a week, the MB 1% was sprayed directly, this lesion was not cleaned by removing skin scales with a scalpel blade before applying the MB. The top image shows the lesion at the start of progress –time 0- (A), the image of the medium shows the lesion at 1 week of treatment (B). and the bottom image shows the lesion at 3 week of treatment (C).

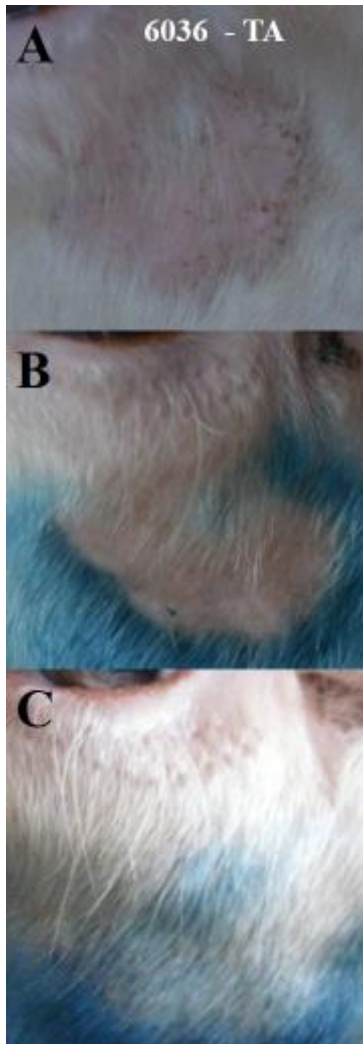
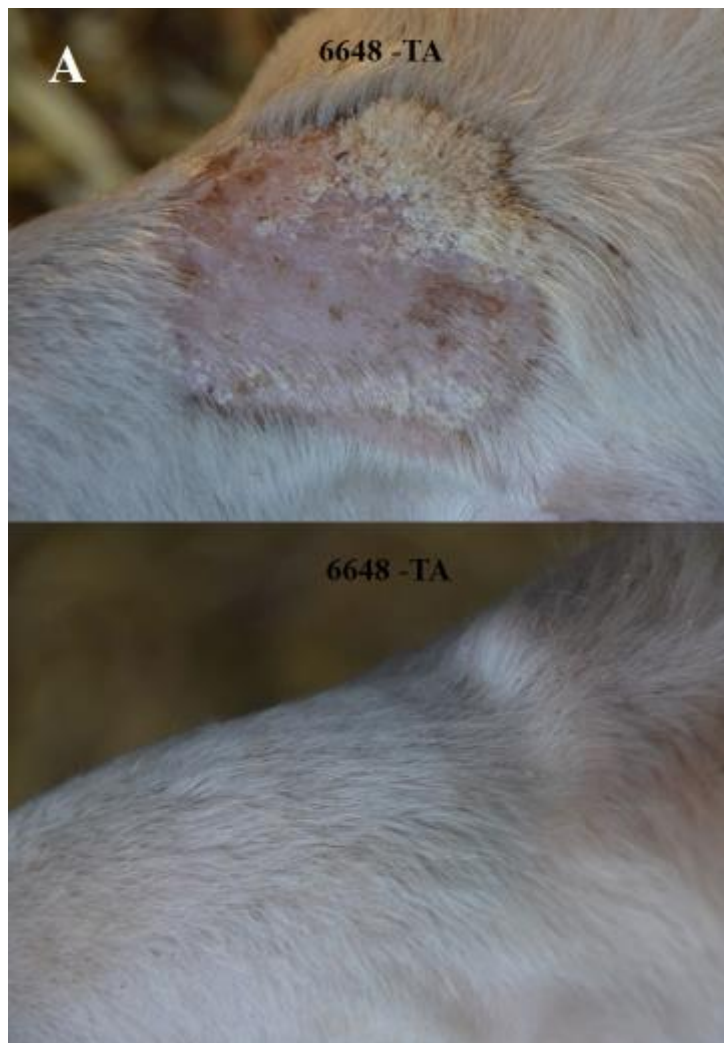
Figure 2: Examples of the lesions in the 6648 –TA sheep treated by applying the PS once a week (A) and the SN2 –TA sheep treated twice (B). The top image shows the lesion at the start of progress, and the bottom image shows the end of treatment.



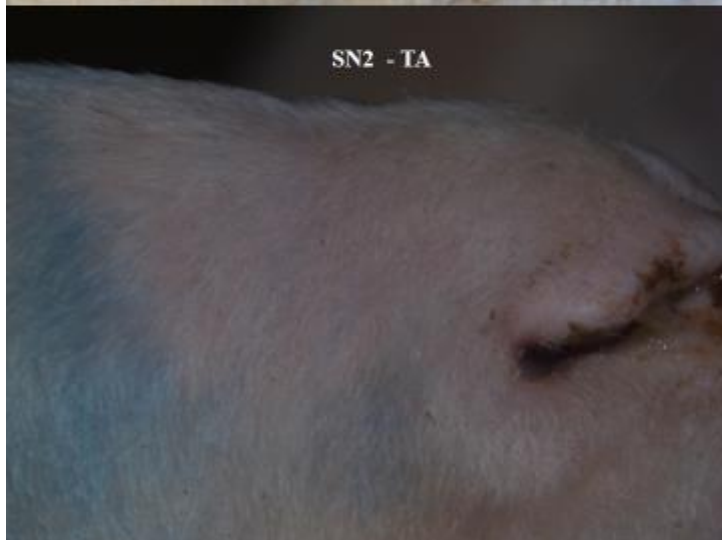
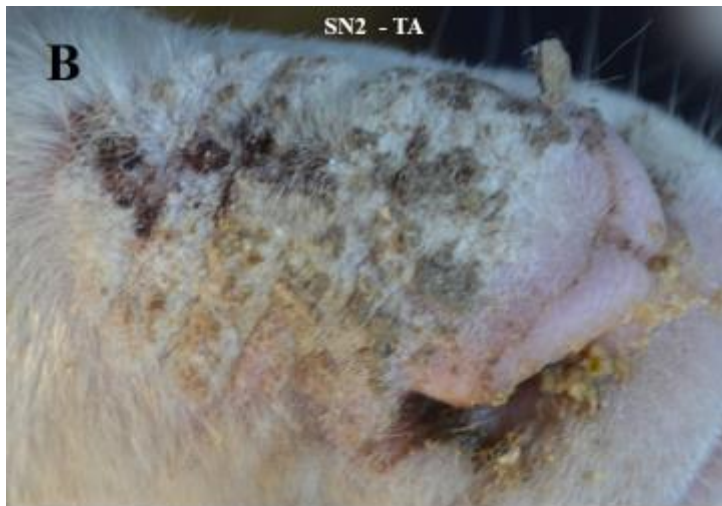


Table 1: Microbiological diagnosis of the ten sheep that constitute the treated group: Plate cultures + KOH determination.

ID samples	Culture	KOH result
SN-1 TA	<i>A.vanbreuseghemii</i>	Yes
6419 TA	negative	Yes
6181 TA	<i>A.vanbreuseghemii</i>	Yes
6110 TA	<i>A.vanbreuseghemii</i>	Yes
6413 TA	<i>A.vanbreuseghemii</i>	No
6648 TA	negative	Yes
6334 TA	<i>A.vanbreuseghemii</i>	No
SN-2 TA	negative	No
6455 TA	<i>A.vanbreuseghemii</i>	Yes
6036 TA	<i>A.vanbreuseghemii</i>	No